

FAILED BACK SURGERY SYNDROME

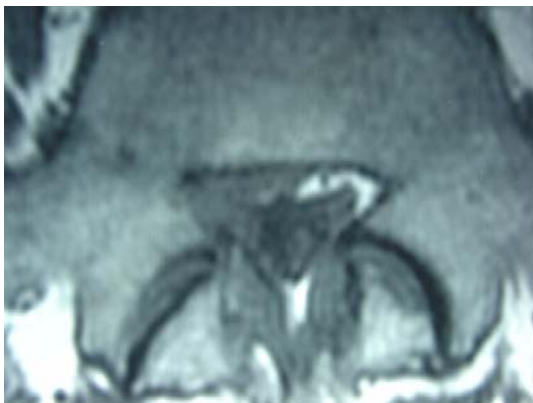

Figure 1

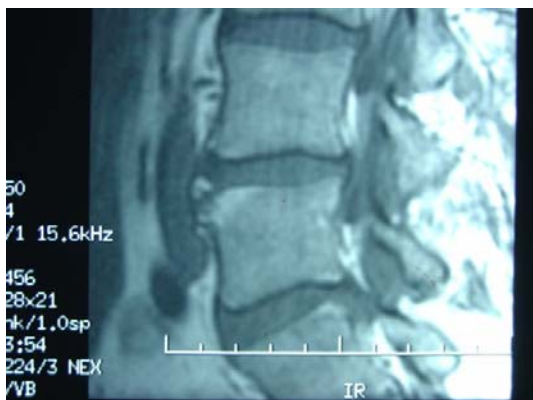

Figure 2

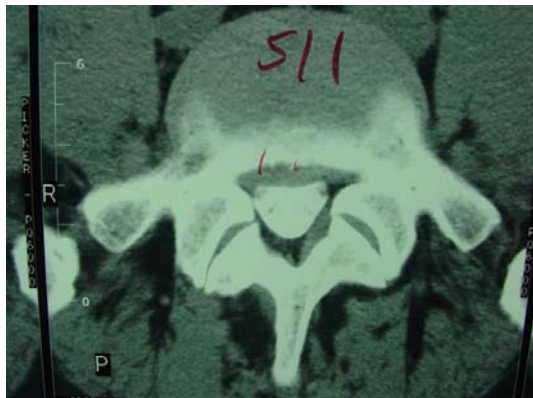


Figure 3

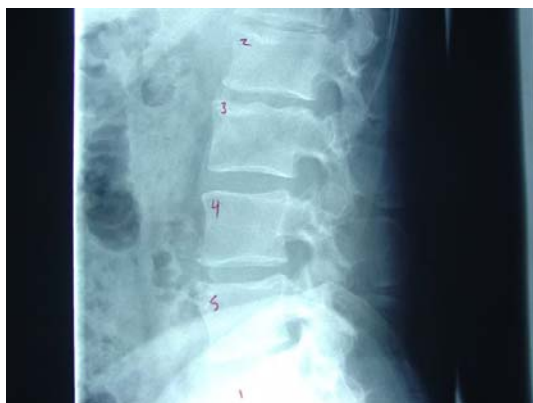

Figure 4

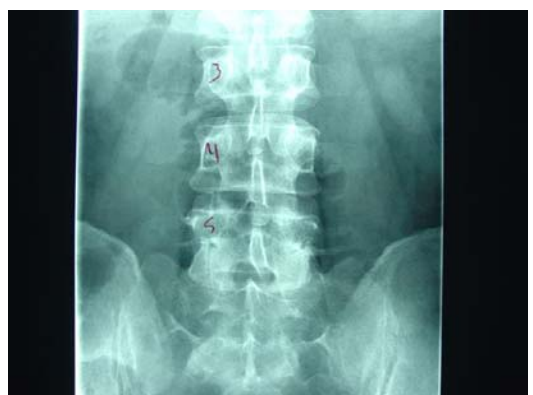

Figure 5

Levine wrote that there are 750 back surgeries done each day and Helfet and Gruebel-Lee pointed out that in a study of 7341 surgical cases, 48% had the pain back one year later. Here is a case that never got relief, only more pain. Please understand that I mention this only as a socioeconomic fact, but this case represents the patient who represents 95% of the cost in treating low back and radicular pain.

Figure 1 is the axial MRI prior to surgery in 2001. There is a right posterolateral sequestered disc lying within the vertebral canal and extending into the lateral recess and osseoligamentous canal. It does contact the cauda equina and exiting right S1 nerve root and probably the L5 dorsal root ganglion.

Figure 2 is the sagittal image showing that the free fragment extends below the posterior sacral base, representing a sequestration. Note the limbus at the superior anterior L4 vertebral plate level.

At this time I had examined this patient, but since he was from a distance in another state and did not want to drive so far to see me, I referred him to a chiropractor in his home town who was not a certified Cox practitioner. He treated him somehow, but the patient ended up in surgery.

Figure 3 is a CT scan, myelographically enhanced, following the surgery because of the intense pain the patient experienced. Note the L5-S1 broad based disc herniation contacting the cauda equina.

Figure 4 is a plain lateral xray showing the L5-S1 degenerative disc disease

Figure 5 looks at the spine posteroanteriorly, making the right L5-S1 facet joints more coronal faced and the left sagittal faced. It is interesting to remember that Cyron and Hutton pointed out the predominance of disc herniation on the side of the more oblique facet in tropism.

(continued next page ...)

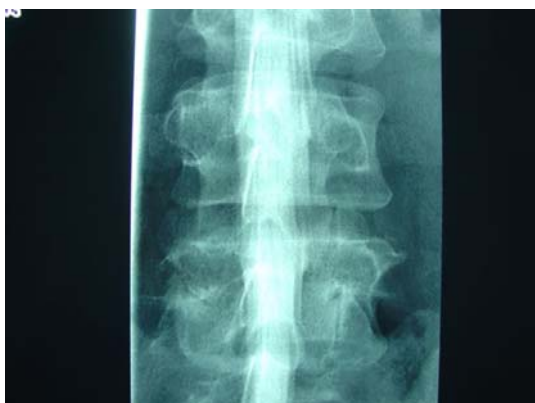

Figure 6

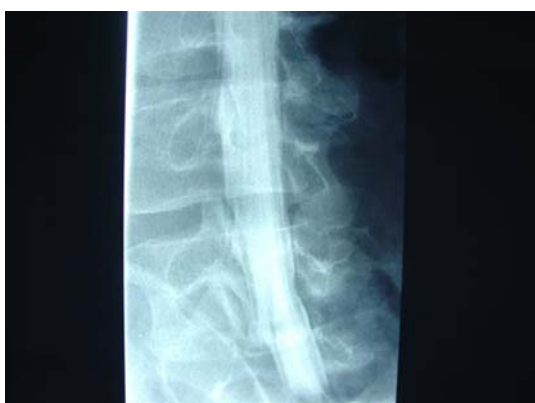

Figure 7

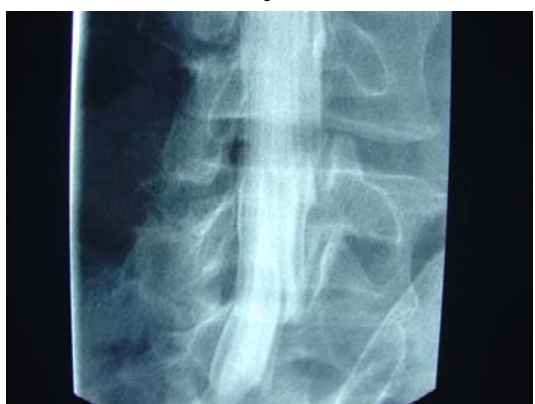

Figure 8

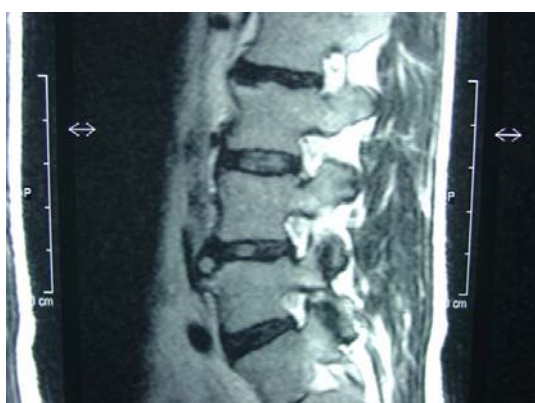

Figure 9

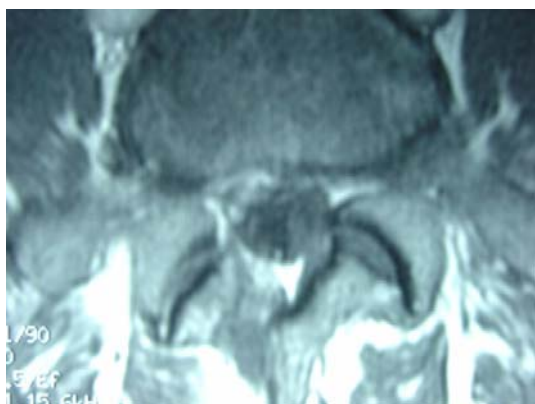

Figure 10

Figure 6 is a myelogram of the lumbar spine showing a slight flattening without indentation of the right exiting S1 nerve root. Remember this xray is looked at anteroposterior so the right and left are switched from 'Figure 5.

Figures 7 and 8 show no amputation of the axillary root sleeves on oblique myelographic study, indicating that the disc is not compressing them. Note I did not say it was not chemically irritating them.

Figure 9 is a sagittal MRI two years after the surgery showing loss of signal intensity of the L2-L3, L5-S1, and L4-L5 discs compared to L3-L4.

Figure 10 is a gadolinium enhanced MRI showing enhancement of the dye within the right posterolateral vertebral canal indicating scar tissue uptake of the dye. Chemical radiculitis is a consideration of the S1 nerve root and/or the L5 dorsal root ganglion.

Follow-up:

This man returns to me three weeks ago, driving a long distance, because nothing else, including prolotherapy, epidural steroid injections, therapies, drugs, and the offer of spinal fusion has helped him. He is treated at my clinic with decompression manipulation of the L5-S1 disc space, followed by negative and positive galvanism into the right L5-S1 disc space into the S1 and L5 nerve complexes. He attends low back wellness school, learns physioball rehabilitation exercises, proprioception balance exercises, and Cox® low back pain exercises. He takes Discat plus, non phosphorous calcium citrate, formula one (minerals, vitamins, amino acids, enzymes). After three weeks, his pain is isolated to the right ankle and low back and gluteal muscles. He is treated now with continued Cox® decompression manipulation Protocol II, gemelli - obturator internus syndrome consisting of obturator internus bursitis and tendinitis of the conjoined tendon insertion of the obturator internus, gemelli inferior and superior, and piriformis into the posterior trochanter of the femur. This hip pain is an area of difficult remission and often the last stage of disc herniation pain. His pain is centralizing nicely. Have you ever noticed the localization of pain into the retrotrochanteric gluteal region in these sciatica patients? I would liked to have treated him prior to the surgery as I think this would have yielded to decompression manipulation and Cox® procedures. You treat them, however, as the patient allows. I will present this case in Alexandria VA this weekend. I am looking forward to it with excitement.

Respectfully submitted,

James M. Cox, D.C., D.A.C.B.R.