

## TWO DISC HERNIATIONS: ONE CONTACTS THE SPINAL CORD, ONE DOES NOT.

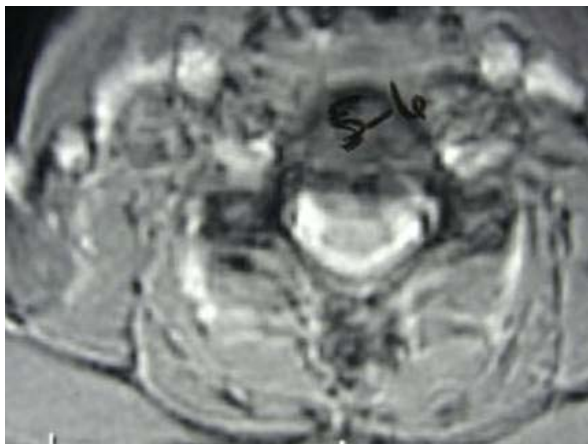


Figure 1 shows the C5-C6 axial image which shows the disc herniation, centrally and broad based, to actually contact the spinal cord.

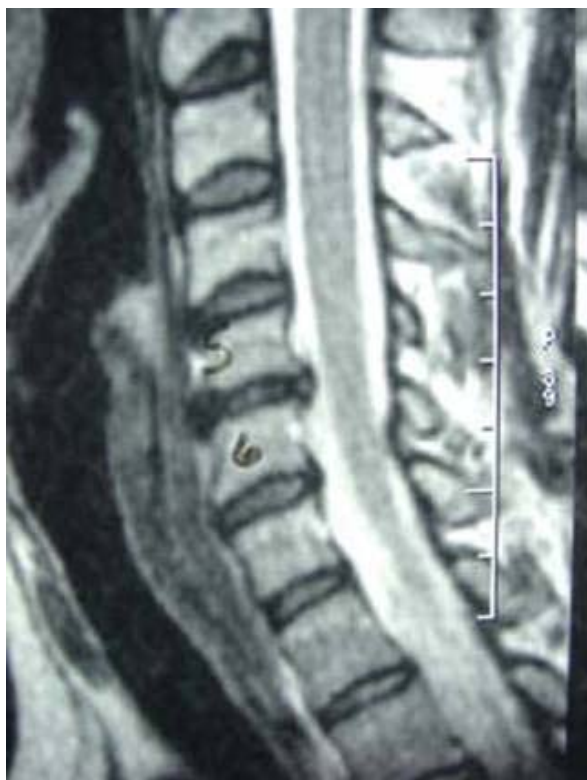

Figure 2 is the sagittal image showing the anterior and posterior C5-C6 disc herniation and the smaller C6-C7 disc herniation.

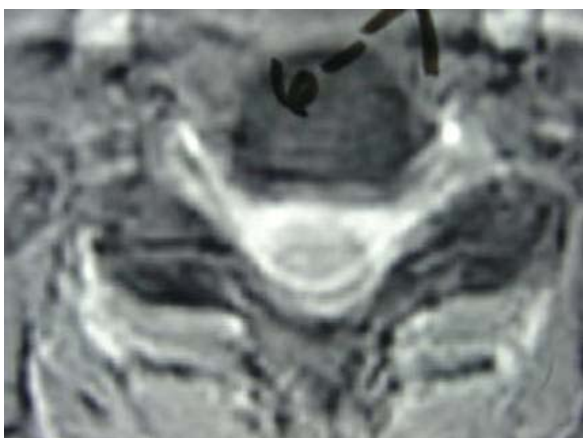

Figure 3 shows that the broad based C6-C7 disc herniation does not contact the spinal cord.

This 46-year-old white, married female school teacher was seen in March 2006 for the chief complaints of cervical, upper thoracic, and right arm pain extending to her hand. She has had this pain for fifteen years and has just completed a course of DRS treatment from September 05 through January 06 which gave approximately 70% relief. She has also tried acupuncture, traditional chiropractic manipulation, and finds that sleeping on her left side gives her relief. She now seeks our treatment with long y axis decompression manipulation of the cervical spine.

Her vital signs are normal. The deep tendon reflexes of the upper extremity are +2 bilaterally. Ranges of motion of the neck are 60 degrees flexion, 30 degrees extension, 20 degrees right lateral flexion, and 30 degrees left lateral flexion with pain. Rotation is 80 degrees to the right and 65 degrees to the left. Marked pain on the left side is noted from C2 through C5-C6. No sensory changes of the upper extremities are noted. Cervical compression is positive. No motor weakness is noted in the upper extremities.

The imaging of this case is quite interesting in that it shows that the C5-C6 disc herniation contacts the spinal cord while that at C6-C7 does not. Note that on the sagittal image, Figure 2, there is a moderate size C5-C6 posterior disc herniation as well as anterior, and a small C6-C7 disc herniation. On axial image, Figure 1, you will see that the C5-C6 broad based disc herniation does indeed contact the spinal cord while the smaller C6-C7 broad based disc herniation, Figure 3, does not contact the spinal cord. Note that the foraminal areas at C6-C7 are relatively patent, while at C5-C6 there is narrowing of the osseoligamentous canals, most marked on the left side. This does not match the patient's symptoms in the right arm, and there are no signs of long tract disease by contact of the C5-6 disc contacting the spinal cord.

Final diagnosis is herniation of the C5-C6 disc and the C6-C7 disc, more marked at the C5-C6 level. This does create right-sided radiculopathy that extends into both the C5 and C6 dermatomes.

She is beginning long-Y axis decompression in our clinic at the C5-6 and C6-7 levels. This follows acupuncture, DRS cervical traction, and traditional chiropractic care. A point in this case is that some disc protrusions are large enough to actually contact the spinal cord and some are small and spare any cord compression, as we see in this case. Hopefully, long Y-axis decompression will give this patient further relief.

Respectfully submitted,  
James M. Cox, DC, DACBR  
3-21-06

[www.coxtechnic.com](http://www.coxtechnic.com)

